



Radiology Rounds

A Newsletter for Referring Physicians
Massachusetts General Hospital
Department of Radiology



Volume 2, Issue 3

March 2004

Janet Cochrane Miller, D.Phil., Author

Susanna I. Lee, M.D., Ph.D., Editor

Vertebroplasty

Vertebroplasty is an image-guided treatment for the alleviation of back pain from vertebral compression fracture. The procedure was first performed in France in 1984, and is now becoming more widely available in the USA. About 85% of compression fractures occur in postmenopausal women and elderly men with osteoporosis. The rest are mostly due to metastatic disease. Osteoporotic vertebral fracture may be caused by normal activity, such as stepping down stairs or opening a window, and has an incidence of 25% in women over age 50. In the majority of osteoporotic fractures, symptoms resolve after 4-8 weeks of restricted activity and treatment with pain medications.

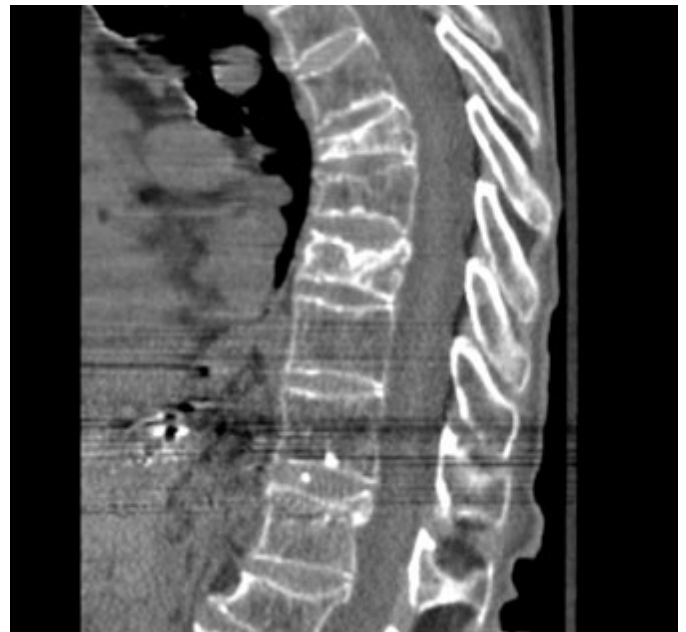Vertebroplasty can provide pain relief and prevent further collapse of fractures that do not heal naturally. The more recent the fracture, the more likely that vertebroplasty will be beneficial. Some patients are candidates for immediate vertebroplasty if they cannot tolerate short-term conservative treatment. These individuals often require hospitalization for pain control. They may be at increased risk for deep venous thrombosis due to bed rest, gastrointestinal irritation due to medications and pneumonia due to respiratory-related pain. Patients with dementia may not be able to remember the need for restricted activity, which limits fracture healing.

Indications for Immediate Vertebroplasty

- Hospitalization due to uncontrolled pain
- Inability to tolerate pain medications
- Inability to tolerate bed rest (high risk for DVT, decubitus ulcer, permanent incapacitation)
- Respiratory compromise due to thoracic pain

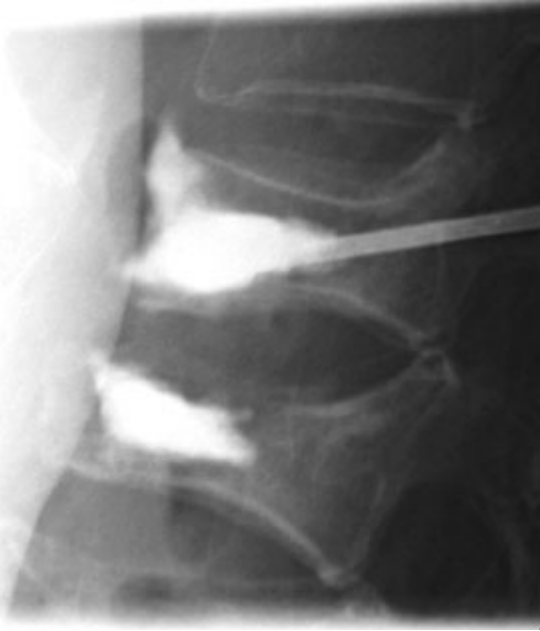Selection of Candidates for Treatment

Patient selection is the critical factor in achieving treatment success. Incidental compression fracture is common in elderly patients with back pain due to other problems, such as disk disease and spinal stenosis. The

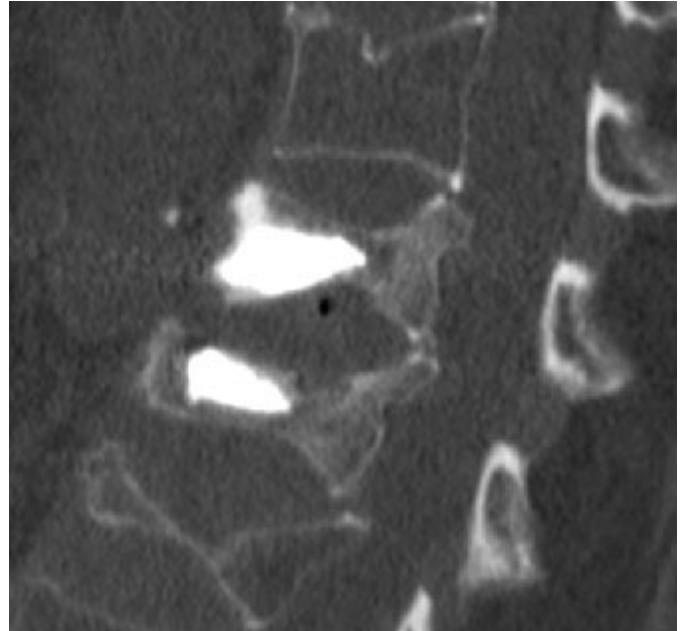


Multiple vertebral fractures seen in a CT saggital reconstruction.

radiologist plays a major role in correlating symptoms with imaging findings, and excluding patients who are unlikely to obtain pain relief from vertebroplasty. Appropriate candidates for the procedure have focal, midline back pain localized to the level of fracture. Pain is worsened with bending, standing or lifting as the day progresses, and is decreased by lying flat in bed. Conventional Radiography can be used to identify a new compression fracture, but radionuclide bone scan, MR or CT is needed to determine whether the fracture is healed or not healed, especially in patients with multiple vertebral compressions. Healed fractures do not necessarily benefit from vertebroplasty. Advanced imaging also helps to distinguish osteoporotic fracture from metastasis or infection, and is necessary to ensure that vertebroplasty can be performed safely.



Bone cement placement shown in X-ray.



CT sagittal reconstruction showing bone cement in vertebrae following treatment.

Contraindications

Active infection is an absolute contraindication. Anticoagulation must be reversed. Fractures that have lost more than 80% of height pose technical challenges and may not respond to vertebroplasty if displaced or retropulsed bone fragments are compressing the spinal cord or other neural structures. Fractures caused by tumor infiltration may not be amenable to vertebroplasty if there is cortical destruction and epidural soft tissue mass. The patient must be able to lie prone for the duration of the procedure. Most patients can tolerate this positioning with conscious sedation.

Clinical Outcome

Partial symptomatic relief occurs immediately and continues to improve over several days or weeks. More than 80% of patients should experience improved quality of life and decreased requirement for pain medications. Vertebroplasty stabilizes the fracture and helps to prevent further collapse of the vertebral body. To avoid additional compression fractures, patients should continue with the treatment of osteoporosis, modify their activities and strengthen their back muscles through physical or occupational therapy.

Potential Complications

The risk of complications is low. Vertebroplasty involves the injection of liquid bone cement into the vertebral body. During injection, leak of cement into the spinal canal can cause compression of neural structures and require surgical removal. Most leakages involve paravertebral veins or disk spaces and rarely cause symptoms. Rib fracture or pedicle fracture can occur during needle placement. Bleeding and infection are rare.

Scheduling

Vertebroplasty may be scheduled through the Musculoskeletal Division (617-726-7717 or 617-724-7246) or through Interventional Neuroradiology (617-726-1767).

Further Information

Patient information on vertebroplasty and other spine treatments for pain management can be found on the [MGH Musculoskeletal Radiology website](#). For further questions about vertebroplasty, contact [William Palmer, M.D.](#), Director of Musculoskeletal Radiology or [Joshua Hirsch, M.D.](#), Director of Interventional Neuroradiology / Endovascular Neurosurgery. An informative webcast showing a live vertebroplasty procedure performed by Dr. Hirsch can be found at www.vertebroplasty.com

References

2001 Mathis, JM, Barr, JD, Belkoff, SM, Barr, MS, Jensen, ME and Deramond, H. *Percutaneous vertebroplasty: a developing standard of care for vertebral compression fractures*. AJNR Am J Neuroradiol **22**: 373-81.

2003 Hodler, J, Peck, D and Gilula, LA. *Midterm outcome after vertebroplasty: predictive value of technical and patient-related factors*. Radiology **227**: 662-8.

2003 Peh, WC and Gilula, LA. *Percutaneous vertebroplasty: indications, contraindications, and technique*. Br J Radiol **76**: 69-75.

© 2003 MGH Department of Radiology

[Janet Cochrane Miller, D. Phil., Author](#)

[Susanna I. Lee, M.D., Ph.D., Editor](#)